

# Anconeus epitrochlearis – prevalence and clinical manifestations

Magdalena Kwiecień<sup>1,A-D</sup>, Łukasz Kuśnierz<sup>1,A-D</sup>, Aleksander Daniluk<sup>1,A,E</sup>, Kaja Iwaniuk<sup>1,A,C,F</sup>, Jakub Buczek<sup>1,B-C</sup>, Zuzanna Białkowska<sup>1,2,B,D</sup>, Maciej Samczuk<sup>1,3,C,F</sup>, Hubert Stachowicz<sup>1,E-F</sup>, Jan Ostański<sup>1,2,A-B,E</sup>, Łukasz Gawłowicz<sup>4,C,E</sup>

<sup>1</sup> Human Anatomy Research Group, Medical University, Lublin, Poland

<sup>2</sup> 1st Military Clinical Hospital with the Outpatient Clinic, Poland

<sup>3</sup> Department of Normal, Clinical and Imaging Anatomy, Medical University, Lublin, Poland

<sup>4</sup> 'MEDYK' Family Medicine Clinic – Non-public Healthcare Facility, Biała Podlaska, Poland

A – Research concept and design, B – Collection and/or assembly of data, C – Data analysis and interpretation, D – Writing the article, E – Critical revision of the article, F – Final approval of the article

Kwiecień M, Kuśnierz Ł, Daniluk A, Iwaniuk K, Buczek J, Białkowska Z, Samczuk M, Stachowicz H, Ostański J, Gawłowicz Ł. Anconeus epitrochlearis – prevalence and clinical manifestations. J Pre-Clin Clin Res. doi: 10.26444/jpccr/185686

## Abstract

**Introduction and Objective.** Anconeus epitrochlearis (AE) is an anomalous accessory muscle discovered in 1865. It arises from the medial epicondyle of the humerus to the olecranon of the ulna. Its appearance is the result of evolution and has benefits as well as deficits that can be harmful. It is believed that if anconeus trochlearis is present, it replaces the Osborne's ligament. The muscle is most commonly detected incidentally during the diagnosis of cubital tunnel syndrome (CuTS). The aim of the study is to review papers on the prevalence of AE, symptoms resulting from its presence, and conclusions drawn from available sources on PubMed.

**Review Methods.** The review is based on 14 papers found in PubMed and PubMedCentral databases after searching for 'anconeus epitrochlearis', 'anconeus epitrochlearis' and 'cubital tunnel syndrome' published between 1874–2023.

**Brief description of the state of knowledge.** Prevalence varies across different types of studies aimed at identifying anconeus epitrochlearis: 8.1%–23% for MRI studies, 4.5%–8.5% for operative reports, and 5.4%–26.5% for cadaveric studies. The mere presence of AE usually does not cause any symptoms. If the presence of anconeus epitrochlearis is symptomatic, patients complain of numbness in the fourth and fifth fingers of the hand and weakness of thenar muscle, which are symptoms of cubital tunnel syndrome (CuTS).

**Summary.** It is likely that AE alone does not cause cubital tunnel syndrome which occurs only when anconeus epitrochlearis undergoes hypertrophy, dispelling doubts about whether the mere presence of the muscle is synonymous with the development of cubital tunnel syndrome. A higher percentage of CuTS was reported in the dominant hand of individuals who had the AE in that limb. Cubital tunnel syndrome caused by the AE is a favourable factor for treatment and post-operative regeneration.

## Key words

cubital tunnel syndrome, skeletal muscle enlargement, prevalence

## INTRODUCTION

In the human body, evolutionary structures emerge with the purpose of adapting the body to new conditions and supporting its functioning; however, their appearance may also be associated with negative effects. One such structure is the anconeus epitrochlearis (AE) muscle (*epitrochleoanconeus*, *epitrochleoolecranonis*, *accessoryanconeus*, *anconeussextus*, *ulnarisinternis*, *cubitalanterieur*), first described by Wood in 1865 and Gruber in 1866. This muscle likely evolved as an extension of the triceps brachii muscle, but it is innervated by the ulnar nerve. The AE runs from the medial epicondyle of the humerus to the olecranon of the ulna, covering the ulnar nerve canal. It is believed that if this additional muscle is present, it replaces Osborne's ligament [1]. Volumetrically, it occupies more space than the ligament, which may compress the ulnar nerve. Therefore, various researchers have sought a correlation between the presence of AE and cubital tunnel

syndrome [2]. The aim of our study is to review the literature on the prevalence of AE in the population and present symptoms resulting from its presence.

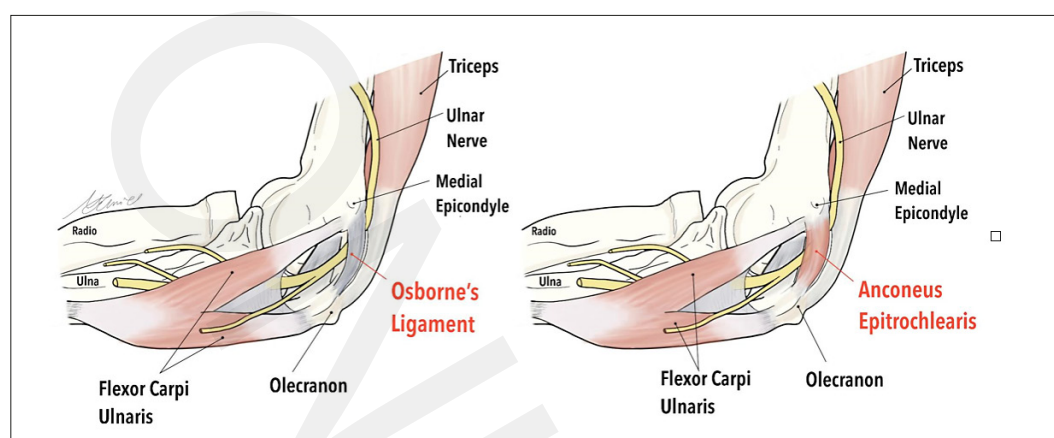
## MATERIALS AND METHOD

A total of 50 papers were found in PubMed and PubMed Central databases under key words 'anconeus epitrochlearis', 'anconeus epitrochlearis' and 'cubital tunnel syndrome'. From these, 14 papers were selected which included data related to the prevalence of the muscle, symptoms associated with its presence, and the conclusions drawn from each respective study. Selected papers ranged from the years 1874–2022 and contained cadaveric studies, case reports, literature reviews, operative reports, MRI studies and one meta-analysis. Some papers combined several of the above-mentioned.

**Prevalence.** In the study by Duran et al. conducted in Turkey in 2022 on 210 examined elbows using MRI, AE appeared 18 times (8.57%). There was no significant difference in the prevalence between different genders. The muscle was more

✉ Address for correspondence: Łukasz Kuśnierz, Human Anatomy Research Group, Medical University, Jaczewskiego 4, 20-400 Lublin, Poland  
E-mail: lukaszkuśnierz133@gmail.com

Received: 10.02.2024; accepted: 05.03.2024; first published: 18.03.2024



**Figure 1.** Anatomy of the ulnar nerve in patients with Osborne's ligament (left) and patients with anconeus epitrochlearis (right)

commonly present in the right arm (72.2%) than in the left (27.8%), but there is no data on which hand was dominant in these patients [3].

In the study by Suwannakhan et al. 2021 from Thailand in 2021, autopsy was performed on 56 patients, examining 112 elbows. The AE muscle was found in 6 elbows (5.4%) [4].

In the study by Maslow et al. in the USA in 2020, images from magnetic resonance imaging taken between 1996 – 2016 were reviewed. Out of 199 patients, the AE muscle appeared in 27 patients (13.6%). A difference in the time of symptom improvement was also observed between patients with and without the AE muscle. The average time of improvement after surgery for the former was 23 days, while for those without the AE muscle – 33.2 days. Additionally, none of the patients with the AE muscle required a re-operation, compared to 4 patients without this muscle who needed a second surgery [5]. In the same study, medical records from surgeries for cubital tunnel syndrome (CuTS) between 1996 – 2016 were examined. Out of 883 patients, the AE muscle appeared in 40 (4.5%) [5].

In the study by Park et al. from South Korea, medical records from 2007 – 2015 of 142 individuals who underwent surgery for CuTS were reviewed. AE appeared in 12 cases (8.5%). It was also noted that the percentage of individuals with CuTS in the dominant hand was significantly higher in patients with the anconeus epitrochlearis (83.3%) than without it (53%). Therefore, a connection between the hypertrophy of the anconeus epitrochlearis and the frequency of CuTS occurrence was observed. It was also noted that the AE muscle appeared 3 times more often in men (9 cases) than in women (3 cases) [6].

In the study by Nascimento et al. 2018 from Brazil, 218 MRI images were analyzed. An additional anconeus epitrochlearis was observed in 29 patients (13.3%) [7].

In the study by Schertz et al. 2017, ultrasound examinations were conducted on 89 elbows of individuals suffering from ulnar nerve neuropathy. The AE muscle was found in 21 the elbows of those examined (24%) [8].

In the study by Wilson et al., medical records of 168 patients treated for CuTS in the USA between 2005 – 2014 were examined. The presence of AE was revealed in 9 of them (5.4%) [1].

In the study by Husarik et al. in 2009 conducted by (Radiological Society of North America), MRI was performed on 60 individuals suffering from cubital tunnel syndrome (CuTS). The AE muscle was observed in 14 (23%) of them [9].

In the study by O'Driscoll et al. 1991 from the USA, dissection was performed on 27 elbows. The AE muscle was dissected in 3 (27%) [10].

In 1874, in a study on 100 cadavers, Prof. Gruber examined 200 elbows. The AE muscle was revealed in 53 – 26 in men and 8 in women. Additionally, it appeared bilaterally in 15 men and in only 4 women. Unilateral occurrence was found in 11 men and 4 women. If the muscle appeared unilaterally, it predominantly occurred in the right hand (12 cases) compared to the left hand (3 cases) [11]. Table 1. summarizes the results of the current review.

There is a correlation between the diagnostic tool used and frequency of detecting AE. In the case of MRI, the frequency is higher (8.1%–23%) compared to intra-operative reports (4.5%–8.5%). The detection frequency on cadavers shows significant variation (5.4–26.5%).

**Clinical manifestations.** Presence of the anconeus epitrochlearis muscle is typically asymptomatic and is found incidentally [3]. Detection of the AE is most commonly a result of investigating the cause of cubital tunnel syndrome (CuTS) with patients present with tingling and numbness in the 4th and 5th fingers, as well as pain around the elbow. Other complaints include swelling around the cubital fossa and thenar muscle weakness and atrophy. The described

**Table 1.** Prevalence of AE reported by researchers

Study (year)	Study type (diagnostic tool)	Population	Number of subjects	Prevalence
Duran et al. (2022)	MRI	Turkish	210	18 (8.6%)
Suwannakhan et al. (2021)	Cadaveric	Thai	112	6 (5.4%)
Maslow et al. (2020)	MRI	USA	199	27 (13.6%)
Maslow et al. (2020)	Intraoperative report	USA	883	40 (4.5%)
Park et al. (2018)	Intraoperative report	Korean	142	12 (8.5%)
Nascimento et al. (2018)	MRI	Brazilian	218	29 (13.3%)
Grewal et al. (2018)	Cadaveric	Not reported	70	6 (7.5%)
Schertz et al. (2017)	USG	French	89	21 (24%)
Wilson et al. (2016)	Intraoperative report	USA	168	9 (5.4%)
Husarik et al. (2009)	MRI	Swiss	60	14 (23.3%)
O' Driscoll et al. (1991)	Cadaveric	USA	27	3 (11.1%)
Gruber et al. (1874)	Cadaveric	British	200	53 (26.5%)

symptoms of CuTS occur with similar frequency in patients with and without the AE muscle [5]. It is worth emphasizing, however, that a relationship has been observed, that if the pain begins at a younger age, symptoms on the ulnar nerve compression appear periodically and last for a shorter time, and the discomfort is more severe during exercise or when the limb is flexed for an extended period compared to rest. This may be associated with the presence of AE [6].

It is suspected that only an overgrown muscle can cause CuTS symptoms by compressing adjacent structures, hence the pain manifestations often affect the dominant hand. The mere presence of the AE does not equate to cubital tunnel syndrome, and even AE may serve as a protective factor for the ulnar nerve. This could be linked to a reduction in the stiffness of the entrance to the cubital tunnel caused by the anconeus epitrochlearis [1].

## DISCUSSION

Anconeus epitrochlearis, which causes pain manifestations, is discovered during the diagnosis of cubital tunnel syndrome. The diagnosis typically begins with a physical examination, followed by electromyography (EMG) or nerve conduction studies (NCS). Conducting these two tests may not definitively confirm the patient's condition, as, for example, in the cases of patients in the studies by Park et al. (2018) in which EMG was performed in a patient with AE, and Zubair et al. (2021) in which EMG and NCS were performed in a patient with AE. No anomalies were observed in the results of these tests. However, in the study by Kim et al. (2018), from a review of records of patients operated on for CuTS, it appears that NCS was normal in some individuals, while abnormal results are observed in the majority [6, 12, 13].

Despite the fact that, as it later turns out, that in patients who have the anconeus epitrochlearis muscle, nerve conduction studies and electromyography may have completely normal results. Therefore, it is crucial to perform ultrasound (USG) or magnetic resonance imaging (MRI) – both methods allow the detection of the additional muscle. In MRI, a muscle with an average length of 18.12 mm  $\pm$  5.42 mm and a volume of an average of 882.94 mm<sup>3</sup>  $\pm$  295.05 mm<sup>3</sup> can be found [7].

After identifying the cause of CuTS, surgery is performed to relieve the patient's pain, to release the ulnar nerve from compression caused by the AE. During the procedure, the anconeus epitrochlearis is removed or, along with the muscle removal, the ulnar nerve is repositioned. Essentially, there is no difference in the later therapeutic outcome regardless of the surgical approach used. However, in the case of nerve transposition surgery, a higher risk of wound infection can be expected [14]. On average, patients experience improvement 23 days after the surgery – 10 days earlier than after surgeries treating CuTS caused by a different reason than AE [5].

## CONCLUSIONS

An anconeus epitrochlearis muscle was present in 4.5% – 27% of the examined population. There is no clear correlation between the type of examination performed and the frequency of detecting the muscle. If the presence is unilateral, the AE tends to occur more frequently in the right hand (72.2%-80%). In the 2018 study by Park et al., it

was also demonstrated that the percentage of individuals who developed cubital tunnel syndrome (CuTS) in their dominant hand is higher in those with the anconeus epitrochlearis in that hand (83.3%), compared to those without this muscle (53%) [6]. Therefore, it can be concluded that since it is the dominant hand, it is used more frequently, and thus, the AE may be more developed, leading to hypertrophy and causing pain symptoms.

It is probable that the anconeus epitrochlearis causing CuTS is not solely due to its presence, but the occurrence of symptoms also requires hypertrophy of AE [6]. CuTS caused by the hypertrophy of anconeus epitrochlearis is a favourable factor for the time of improvement after surgical intervention. On average, patients experienced improvement after 23 days (for comparison, patients after non-anconeus epitrochlearis-related surgery felt improvement after an average of 33.2 days). Moreover, none of the patients with the AE required additional surgery, compared to 10% of patients without this muscle [5].

In summary, anconeus epitrochlearis becomes a significant factor in treating patients with cubital tunnel syndrome. At this point, it cannot be definitively stated whether the presence of the muscle alone will cause CuTS, or only its hypertrophy, or conversely, whether it serves a protective function for the nerve. This uncertainty is due to the limited amount of available literature, underscoring the need for more detailed research in this area.

## Acknowledgement

The authors extend their sincere thanks to Dr Magdalena Chmiel for creating the illustration for the review.

**Conflict of interest.** The authors declare no conflict of interest.

**Funding.** No external funding was received to perform this review.

## REFERENCES

1. Wilson TJ, Tubbs RS, Yang LJS. The anconeus epitrochlearis muscle may protect against the development of cubital tunnel syndrome: a preliminary study. *J Neurosurg.* 2016;125(6):1533–1538. doi:10.3171/2015.10.JNS151668
2. Cammarata MJ, Hill JB, Sharma S. Ulnar Nerve Compression due to Anconeus Epitrochlearis: A Case Report and Review of the Literature. *JBJS Case Connect.* 2019;9(2):e0189. doi:10.2106/JBJS.CC.18.00189
3. Duran S, Gunaydin E, Cayhan V. The prevalence of the anatomical variation in a Turkish population: supernumerary muscle-anconeus epitrochlearis. *Surg Radiol Anat.* 2022;44(10):1409–1415. doi:10.1007/S00276-022-03021-7
4. Suwannakhan A, Chaiyamon A, Yammine K, et al. The prevalence of anconeus epitrochlearis muscle and Osborne's ligament in cubital tunnel syndrome patients and healthy individuals: An anatomical study with meta-analysis. *Surgeon.* 2021;19(6):e402-e411. doi:10.1016/J.SURGE.2020.12.006
5. Maslow JI, Johnson DJ, Block JJ, Lee DH, Desai MJ. Prevalence and Clinical Manifestations of the Anconeus Epitrochlearis and Cubital Tunnel Syndrome. *Hand (N Y).* 2020;15(1):69–74. doi:10.1177/1558944718789412
6. Park JJ, Kim HM, Lee JY, et al. Cubital Tunnel Syndrome Caused by Anconeus Epitrochlearis Muscle. *J Korean Neurosurg Soc.* 2018;61(5):618–624. doi:10.3340/JKNS.2018.0033
7. Nascimento SRR, Ruiz CR. A study on the prevalence of the anconeus epitrochlearis muscle by magnetic resonance imaging. *Rev Bras Ortop (Sao Paulo).* 2018;53(3):373–377. doi:10.1016/J.RBOE.2018.03.015

8. Schertz M, Mutschler C, Masmajeau E, Silvera J. High-resolution ultrasound in etiological evaluation of ulnar neuropathy at the elbow. *Eur J Radiol.* 2017;95:111–117. doi:10.1016/j.ejrad.2017.08.003
9. Husarik DB, Saupe N, Pfirrmann CWA, Jost B, Hodler J, Zanetti M. Elbow nerves: MR findings in 60 asymptomatic subjects—normal anatomy, variants, and pitfalls. *Radiology.* 2009;252(1):148–156. doi:10.1148/RADIOLOGY.2521081614
10. O'Driscoll SW, Horii E, Carmichael SW, Morrey BF. The cubital tunnel and ulnar neuropathy. *J Bone Joint Surg Br.* 1991;73(4):613–617. doi:10.1302/0301-620X.73B4.2071645
11. Galton JC. On the Epitrochleo-Anconeus or Anconeus Sextus (Gruber). *J Anat Physiol.* 1874;9(Pt 1):168.2–175. <https://www.ncbi.nlm.nih.gov/pmc/articles/PMC1319039/>
12. Zubair AS, Wang A, Roy B. Ulnar neuropathy from accessory epitrochlearis anconeus muscle. *Neurol Sci.* 2022;43(3):2165–2166. doi:10.1007/S10072-021-05713-1
13. Kim N, Stehr R, Matloub HS, Sanger JR. Anconeus Epitrochlearis Muscle Associated With Cubital Tunnel Syndrome: A Case Series. *Hand (N Y).* 2019;14(4):477–482. doi:10.1177/1558944718762566
14. Caliendo P, La Torre G, Padua R, Giannini F, Padua L. Treatment for ulnar neuropathy at the elbow. *Cochrane Database Syst Rev.* 2016;11(11):CD006839. doi: 10.1002/14651858.CD006839.pub4.